

# Skin-reducing mastectomy and immediate hybrid breast reconstruction using combination of acellular pericardium matrix and de-epithelialized dermal flap in patients with medium and large hypertrophic and ptotic breasts

*D. Varvaras<sup>1</sup>, A. Sachoulidou<sup>2</sup>, V. De Felice<sup>1</sup>, F. Frusone<sup>1</sup>, G. Papadopoulos<sup>3</sup>, S. Tardioli<sup>4</sup>, S. D'Onofrio<sup>5</sup>, T. Al Lawati<sup>6</sup>, H. Nina<sup>7</sup>*

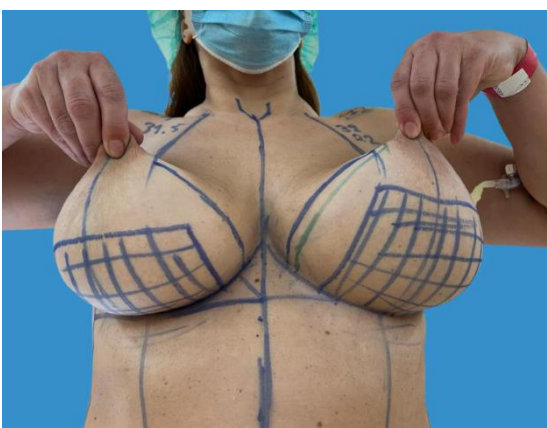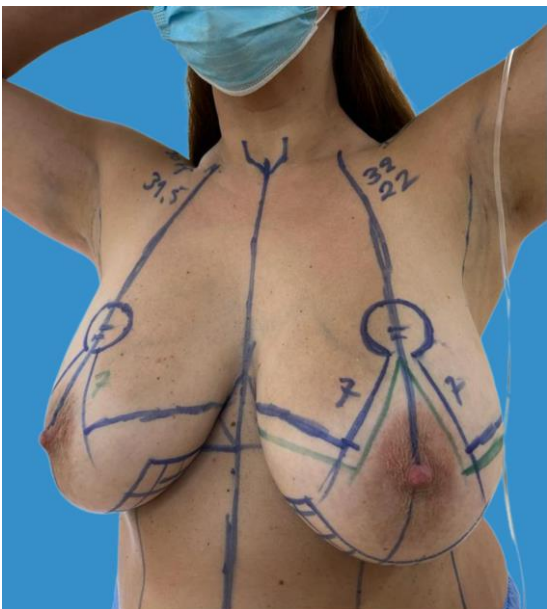
<sup>1</sup>Surgery, Tiberia Hospital, Rome, Italy, <sup>2</sup>Second Department of Propaedeutic Surgery, Aristotle University of Thessaloniki, Thessaloniki, Greece, <sup>3</sup>Breast Imaging Division - Department of Radiology, Tiberia Hospital, Rome, Italy, <sup>4</sup>Breast Imaging Division - Department of Radiology, Casa di Cura INI, Grottaferrata, Italy, <sup>5</sup>Euromedica Geniki Kliniki, Thessaloniki, Greece, <sup>6</sup>Surgery, Royal Hospital, Muscat, Oman, <sup>7</sup>Breast Imaging Division - Department of Radiology, San Carlo di Nancy, Rome, Italy, <sup>8</sup>Surgery, University Medical Center of Tirana Mother Teresa, Tirana, Albania

## Introduction

Medium and large-sized breasts with grades II and III ptosis are difficult to approach and a type IV skin sparing mastectomy is often required to achieve a safe oncologic result and aesthetically pleasing reconstruction in a single-stage operation by use of anatomical permanent implants into a pre-pectoral large pocket made by the conjunction of the de-epithelialized inferior dermal flap with an acellular pericardium matrix (APM) to achieve complete implant coverage.

Pre-pectoral implant-based breast reconstructions using biological meshes have recently gained popularity.

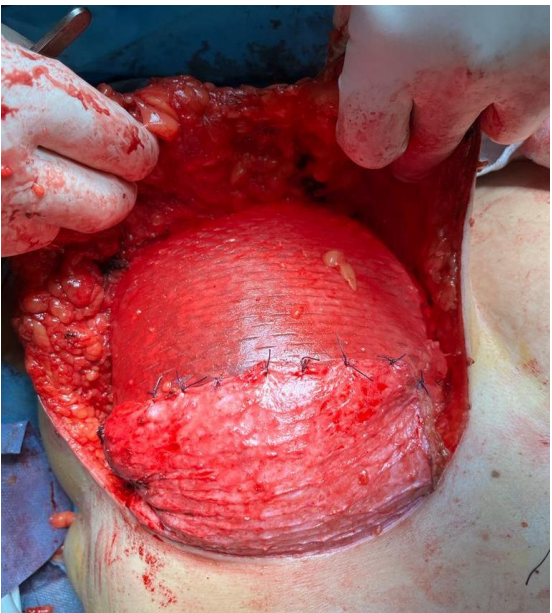
We adopted the term “hybrid” reconstruction to describe this technique. There is limited data on the safety of performing a skin-reducing mastectomy with an immediate pre-pectoral implant reconstruction in women with large and ptotic breasts.



## Materials and method

The data was collected from October 2020 to November 2022. Early complications, including infection, tissue necrosis, seroma, hematoma, and implant loss, were analyzed. Data including age, body mass index (BMI), mastectomy weight, and risk factors for postoperative complications were collected retrospectively for patients undergoing a skin-reducing mastectomy and an immediate hybrid reconstruction.

To perform reconstructions, an acellular pericardium matrix was used and sutured to the superior border of the inferior pedicle dermal flap. An anatomical implant was then inserted into the pouch. Skin flaps were finally closed down to the inframammary fold.



After histologic exam to confirm the lack of retroareolar tissue infiltration the nipple was preserved. In 2 breasts, the nipple-areolar complex (NAC) was resected for oncological reasons; of the 28 preserved, 26 underwent grafting, and 2 underwent elevation through the superior pedicle flap. Contralateral symmetrization was performed in the same operation.

All selected patients satisfied inclusion criteria either for nipple-sparing mastectomy or prophylactic mastectomy. We selected patients who had large ptotic breasts: areola-submammary fold >8 cm and jugular-nipple distance >25 cm.

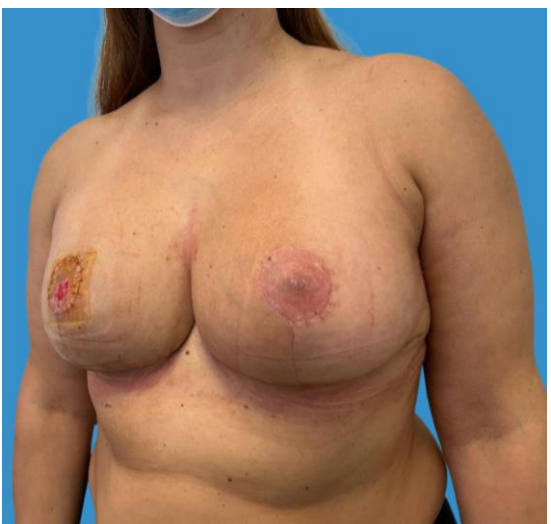
## Results

A total of 22 patients enrolled and operated on based on the proposed technique, accounting for a total of 30 breasts (10 cases were bilateral). Twenty patients had cancer; and two underwent prophylactic surgery;. In all cases, a definitive prosthesis was placed in a single surgical period.

The BMI was greater than 28 kg/m<sup>2</sup> in 52% of patients and the average mastectomy specimen weight was 985 g. The average patient age was 51. The medium size anatomical implants was 485 cc.

Twelve women achieved symmetrization in a single stage ending in a symmetric inverted-T scar. There were five complications (16,6%): three seromas (9,96%), one necrosis at the "T" junction (3,32%), and one total NAC necrosis (43,32%). Both were active smokers and obese. Not requiring implant removal.

The outcomes were as follows: excellent in 18 patients, good in 2, and poor in 2.



## Conclusions

The technique described is an effective and reproducible method of immediate hybrid breast reconstruction using implants and acellular pericardium matrix in a single stage in patients with large breasts. The final scars imitate those of cosmetic surgery. Careful patient selection and improvement in the learning curve may reduce the complication rate.